Abdominal wall

•The abdomen is a body area extends b/w the thorax and the pelvis , its upper surface is formed by the diaphragm , downward till pelvic bones where the abdomen ends and pelvis starts .

•Topographical Division of the abdomen :

Particularly used to describe the location of abdominal organs and the pain associated with different abdominal problems , two schemes most often used :

(1) A four-quadrant pattern .

(2)A nine-region pattern .

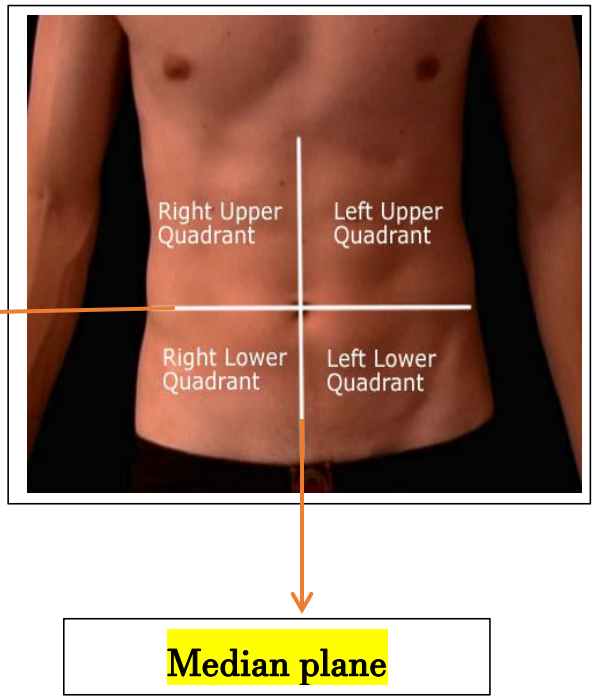

•In nine-region pattern , 2 h and 2 v planes are used :

(1) Superior horizontal : subcostal ;immediately inferior to the costal margins,which places it at the lower border of costal cartilage of rib X , post through the body of L3.

•Transpyloric plane , halfway b/w the jugular notch and superior border of pubic symphysis approx at the level of L1, sometimes used instead .

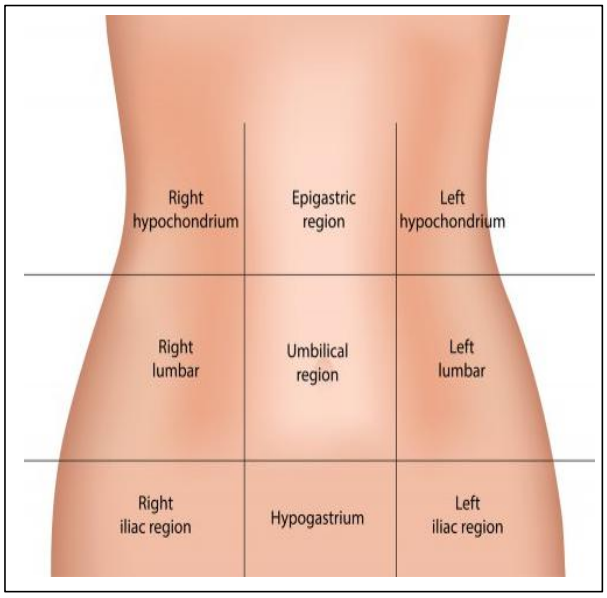

(2) Inferior horizontal ; intertubercular plane passes through the iliac tubercles ,post passes through the upper part of the body of L5

(3) Vertical planes passes from the midpoint of the clavicles inferiorly to a point midway b/w the ant and sup iliac spine(ASIS) and pubic symphysis .

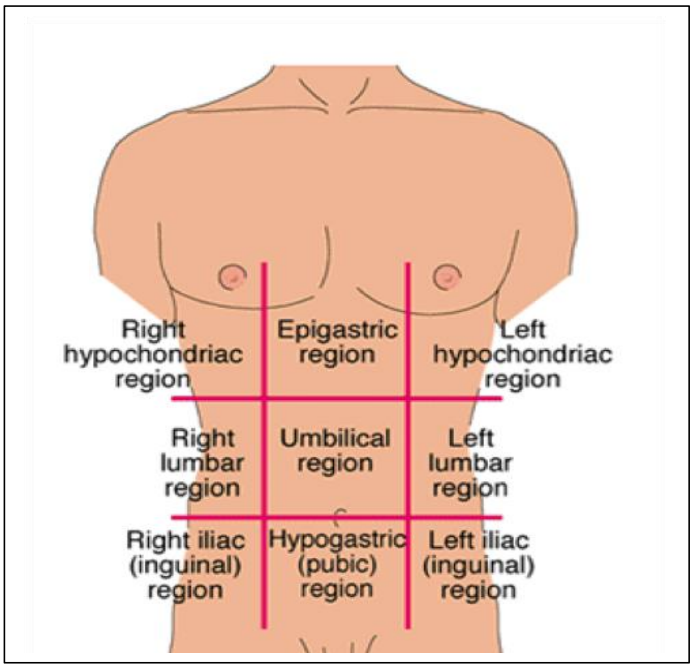

Abdominal wall layers :

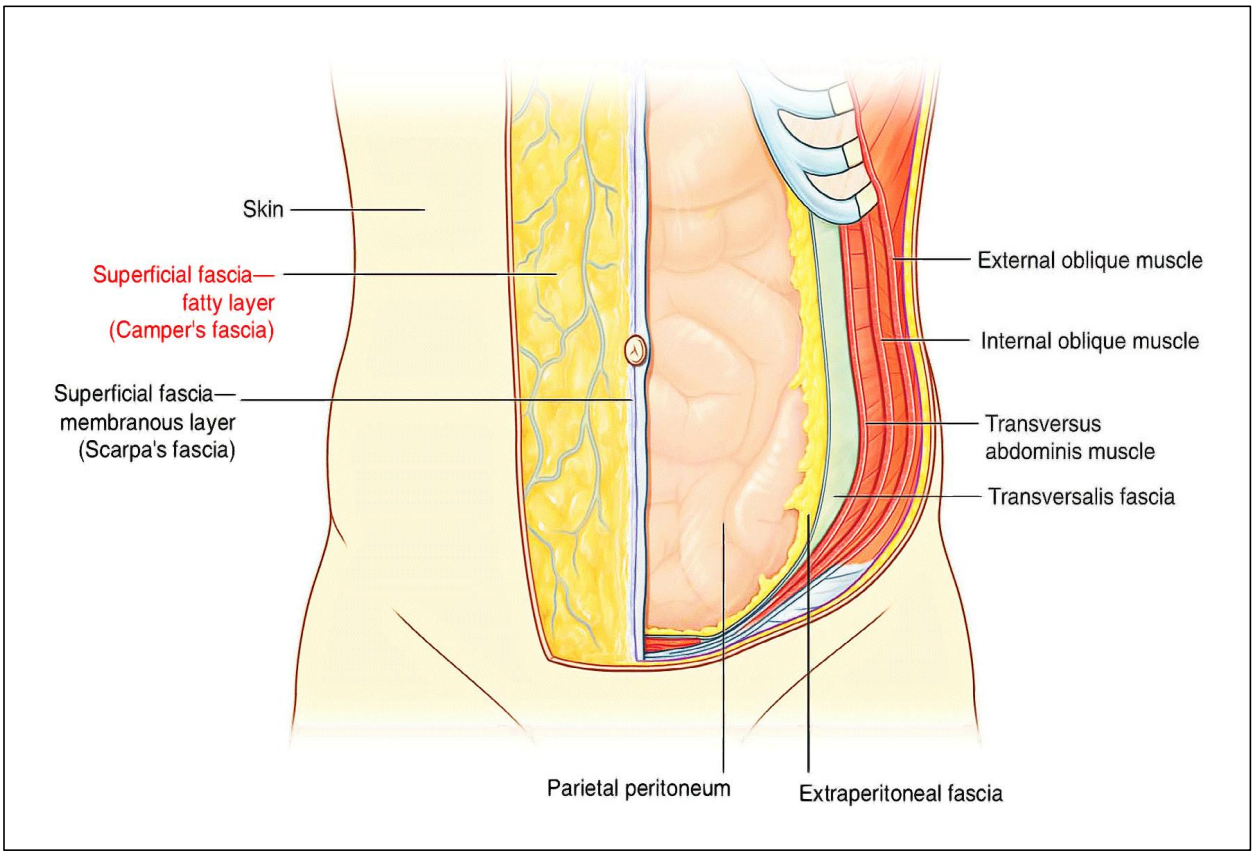

•The abdomen externally is covered by the skin ,underneath the skin there is superficial fascia which is double -layered , the first is the fatty layer (aka camper's fascia) the second is the membraneous layer(aka Scarpa's fascia) , contains little or no fat .
•Scarpa's fascia usually well-developed just below the umbilicus(where it is prominent and relatively thicker) attached down to the iliac crest , down to the iliotibial tract(IT band).
•Inferiorly , Scarpa's fascia continues into the thigh , but just below the inguinal lig it fuses with deep fascia of the thigh .

Abdominal nerve supply :

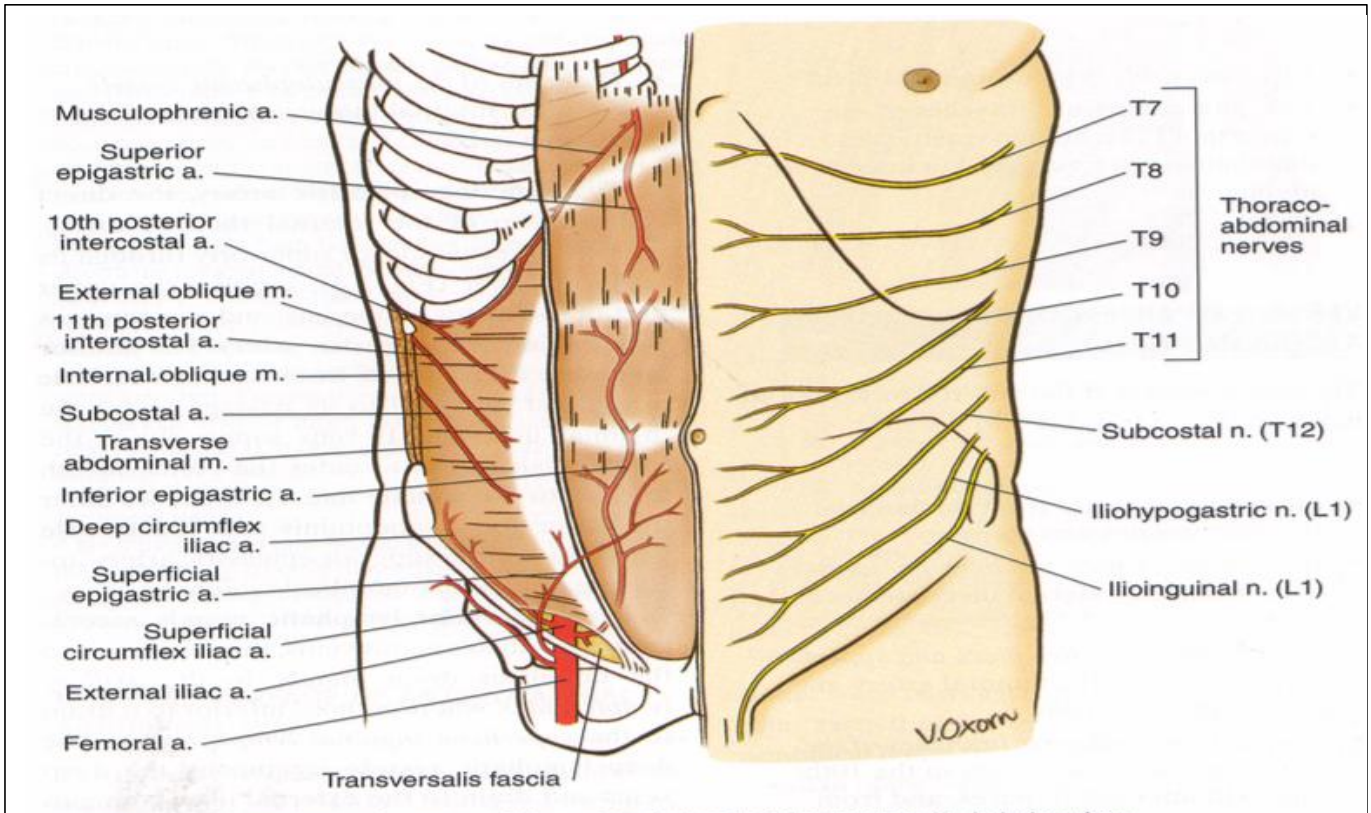

FIGURE 3.6 **Arteries and nerves of the anterolateral abdominal wall.** Anterior view.

•Skin ,muscles and perietal peritoneum of the antero-lateral abdominal wall are supplied by T7-T12 and L1 spinal nerves .

•T7-T11 --> Intercostal nerves , leaving intercostal spaces deep to the costal cartilages ,and continue to supply the abdomen (from the xiphoid process to just above the umbilicus)
•Umbilicus region is supplied by :T10 .
•T12(Subcostal/hypocostal/infracostal nerve) supplies along with L1 (Ilio-hypogastric nerve)the area just below the umbilicus to , and including , the pupic region .
•Additionally , ilio-inguinal nerve(branch of L1) supplies the ant surface of the scortum (male)or labia majora(female) , also sends cutaneous branches to the thigh .

Blood Supply of the abdomen

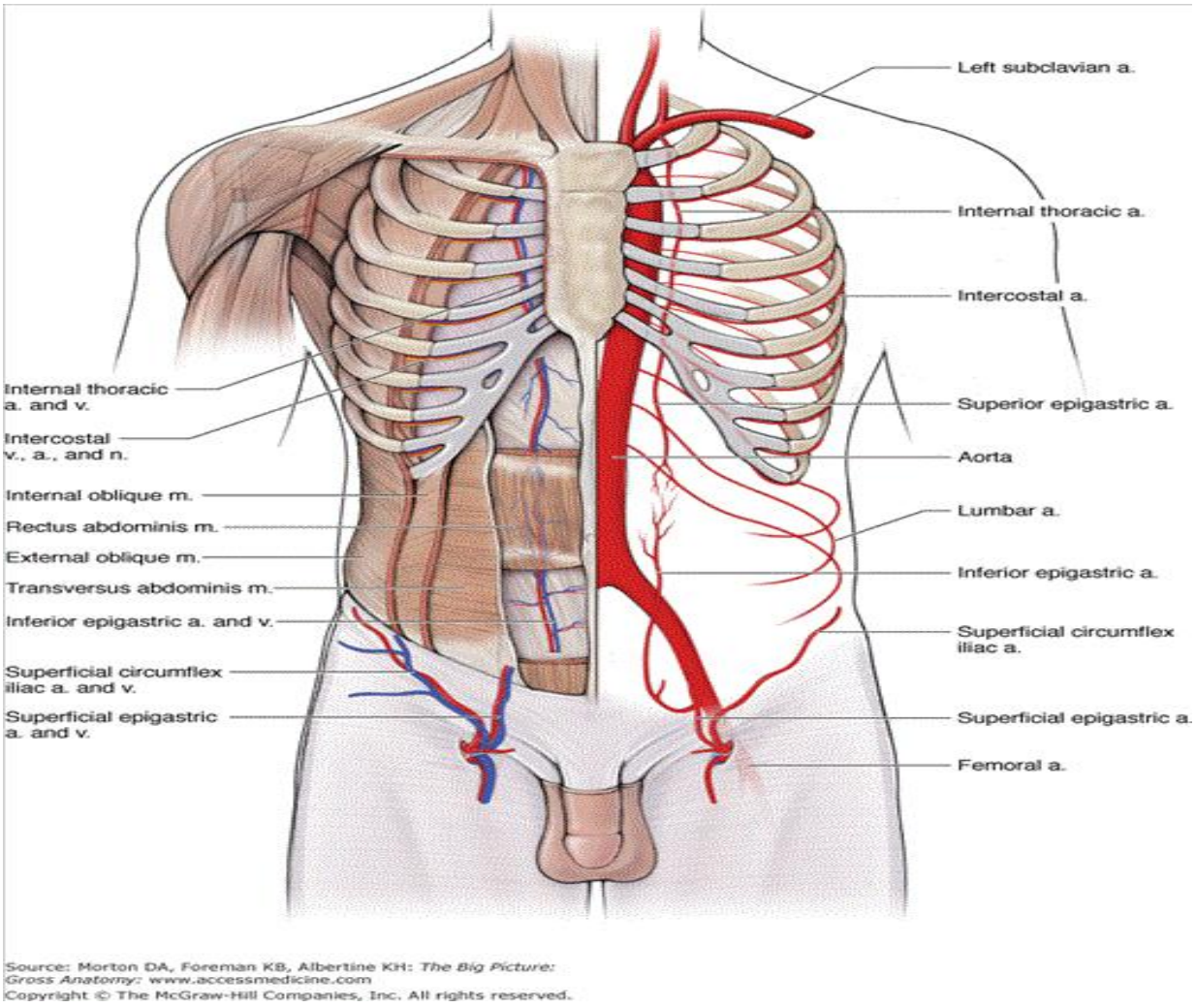

•Deep :

>The *superior pt of the wall* is supplied by the *superior epigastric a.* , a branch of *internal thoracic a.* (itself is a branch of SC a.).

>The *lateral pt of the wall* is supplied by branches of *10th and 11th intercostal arteries* and the *subcostal a.*

>The *inferior pt of the wall* is supplied by medially placed *inferior epigastric a.* and laterally placed *deep circumflex iliac a.* , both are branches of the *external iliac a.*

•Femoral a. gives off 2 important branches ; *superficial epigastric a.* (medially)and *superficial circumflex iliac a.*(laterally) which are resposible for supplying the inferior pt of abdominal wall superficially .

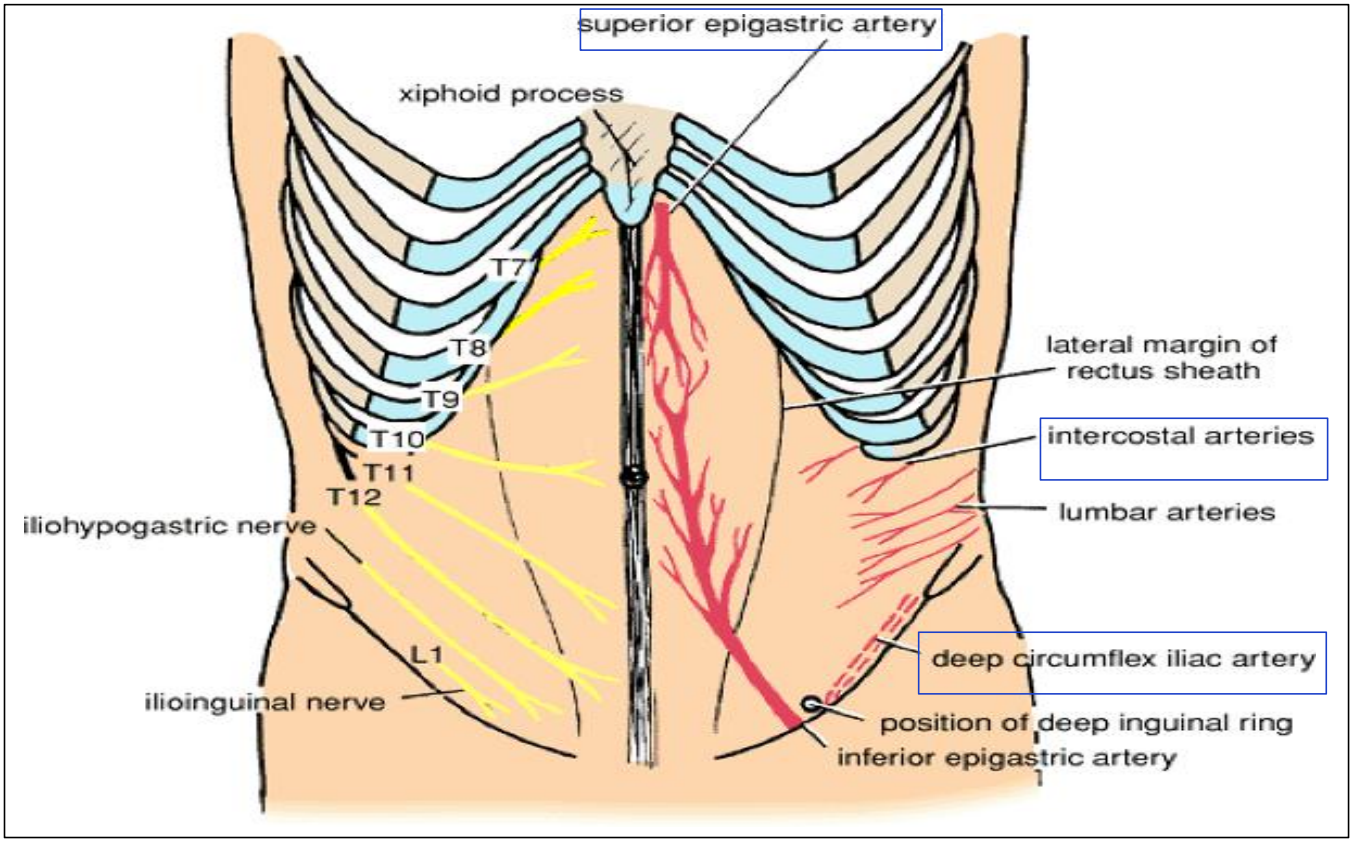

Révision of pelvic anatomy

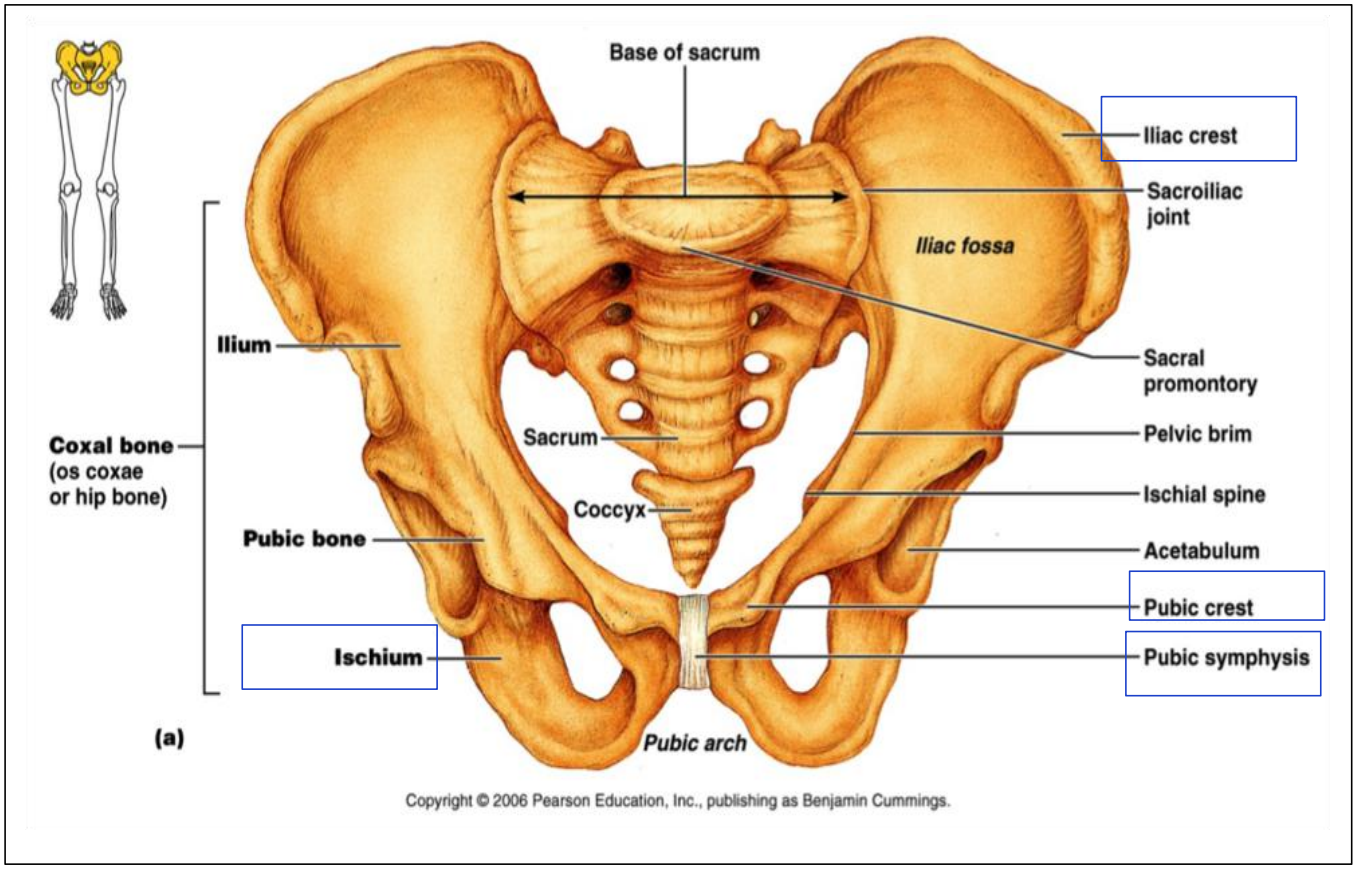

Notes to remember :

(1) Pubic symphysis is located b/w the lt and Rt pubic bones near the midline of the body .

(2) The three articulations of each hip bone :

A. Sacroiliac joint : with the sacrum

B. Pubic symphysis : with the other hip bone المفصل الأمامي

C. Hip joint : with head of the femur

(3) Pubis being anterior and ischium posterior .

(4) Pubis forms anteroinferior part of hip bone , consists of body , superior ramus and inferior ramus .

(5) Ischium is posteroinferior part of the hip bone , consists of a body and a ramus .

(6) Acetabulum ; hemispherical cavity on the lateral aspect of the bone , formed by :

A. Ilium

B. Pubis

C. Ischium

(7)Iliac crest ;the upper end of the ilium (topmost portion) ends anteriorly with ASIS , posteriorly with PSIS

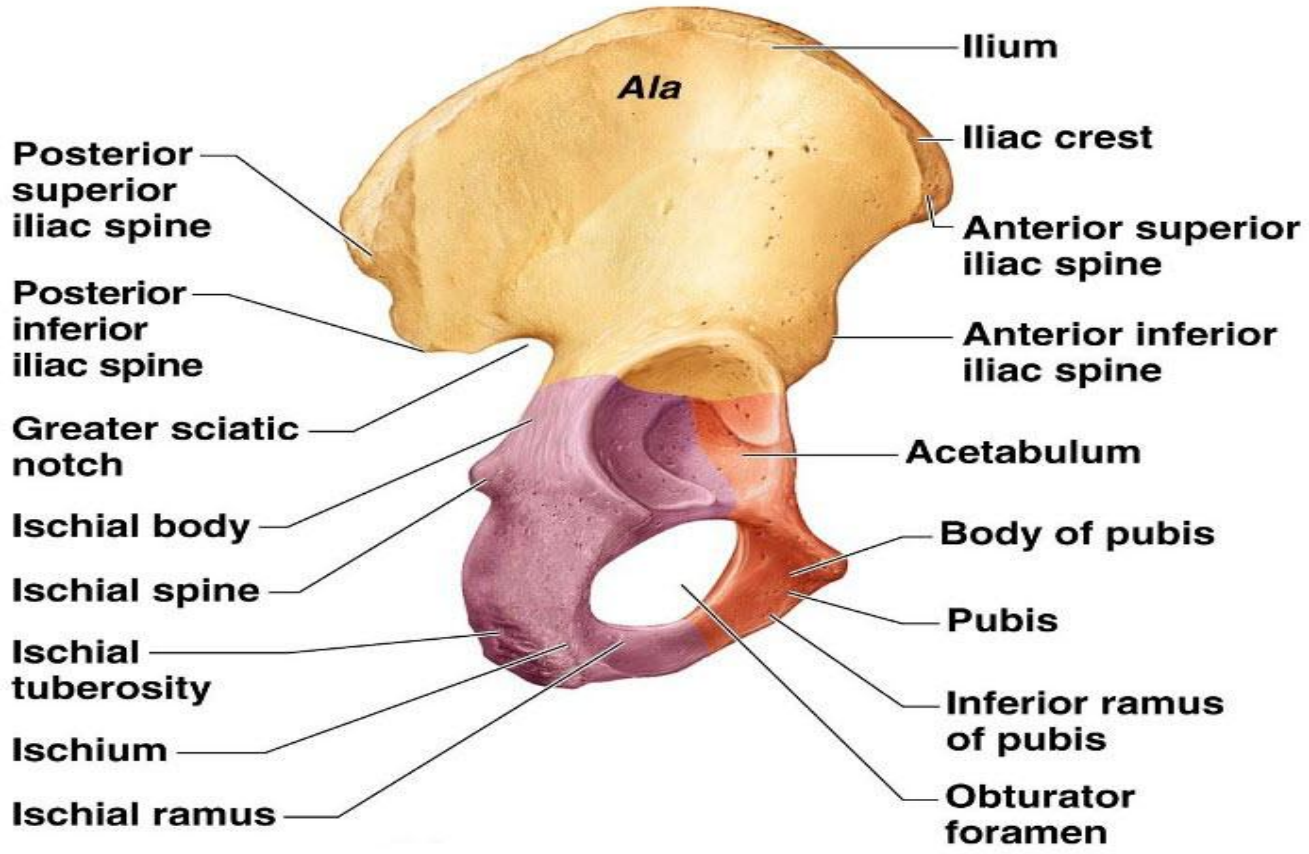

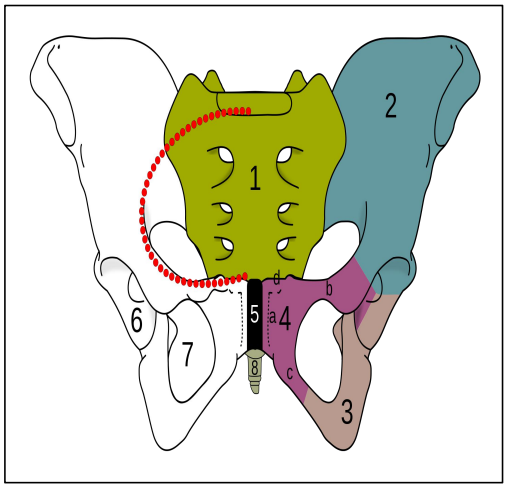

Iliopectineal line

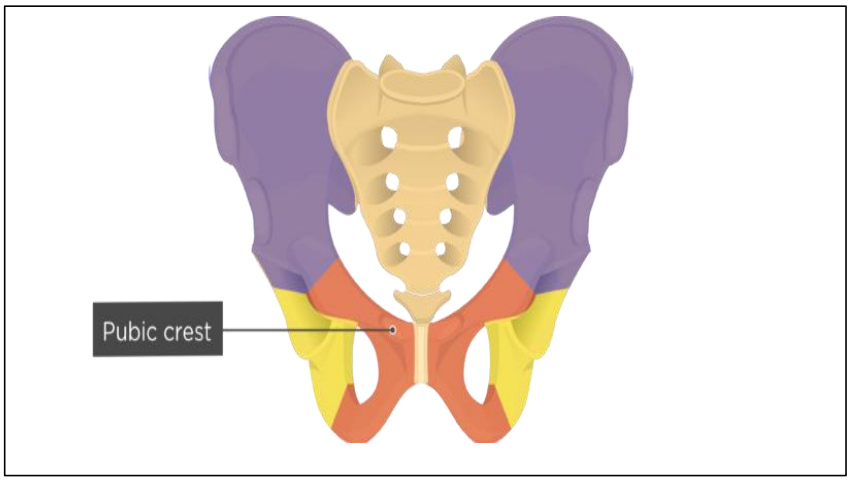

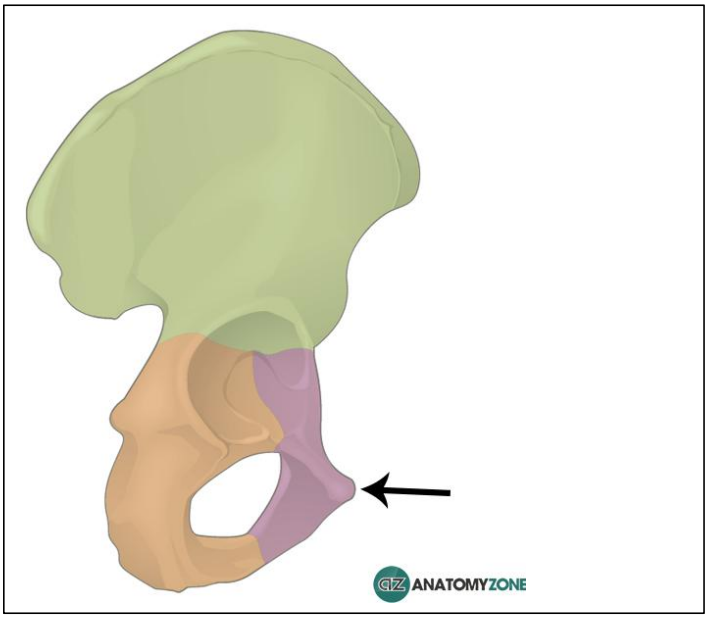

Pubic Tubercle

•Inguinal lig , extends from ASIS to the pubic tubercle.

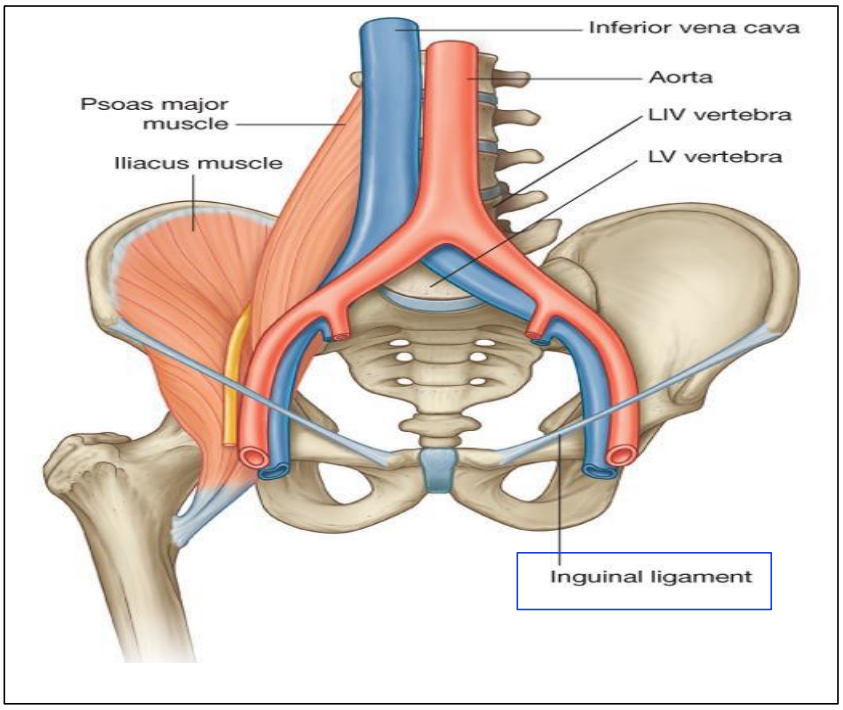

Muscles of the abdominal wall :

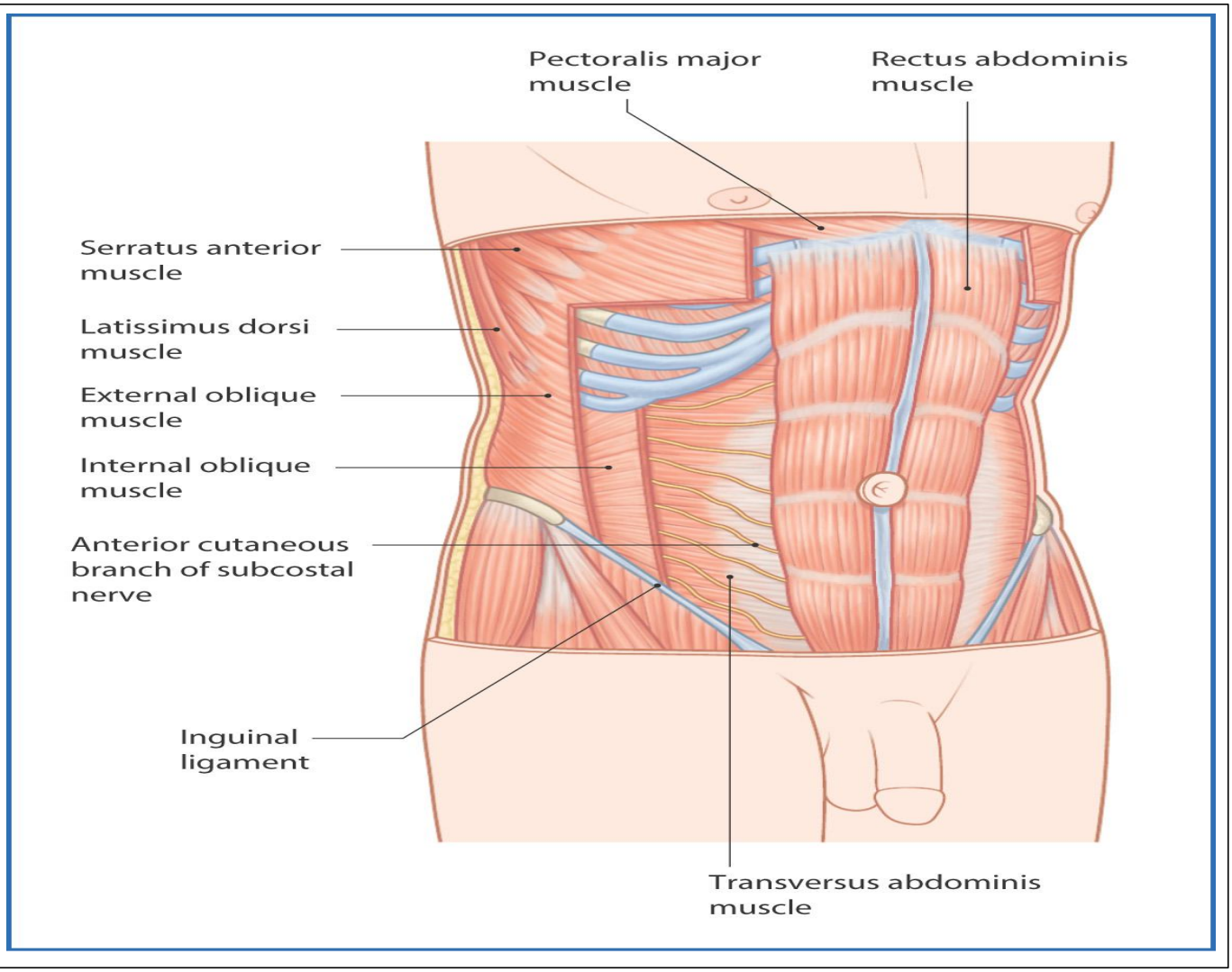

(1) Rectus Abdominis Muscle

•Paired muscle , runining vertically on each side of anterior abdominal wall .

•Origin:

5^{Th} , 6th ,7th costal cartilages and Xiphoid process

•Insertion :

Pubic Crest

•Along its course , it is intersected by 3 or 4 Transverse fibrous bands called : Tendinous Intersections ,which indicates that this muscle during embryonic life has formed by union of different parts (more than 1).

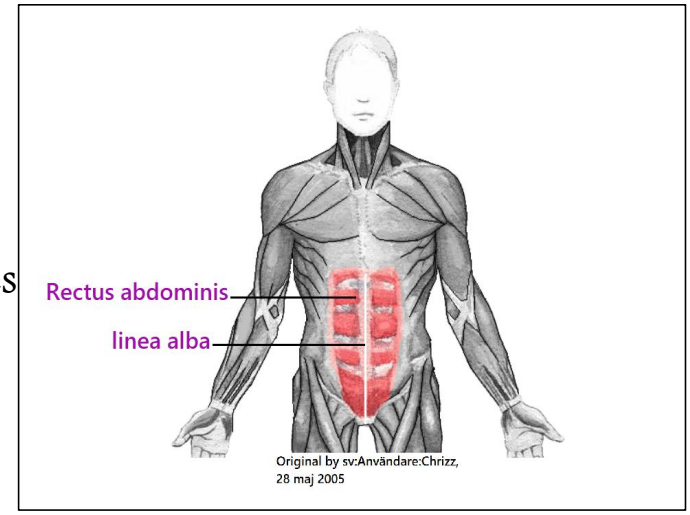

•Rectus Abdominis Muscle , is surrounded by a membrane (anteriorly and posteriorly) respictively called : Anterior Rectal Sheath , Posterior Rectal Sheath. These two meets in the midline , forming a fibrous structure running down from the xiphoid process to the pubic symphysis called Linea Alba(White line).

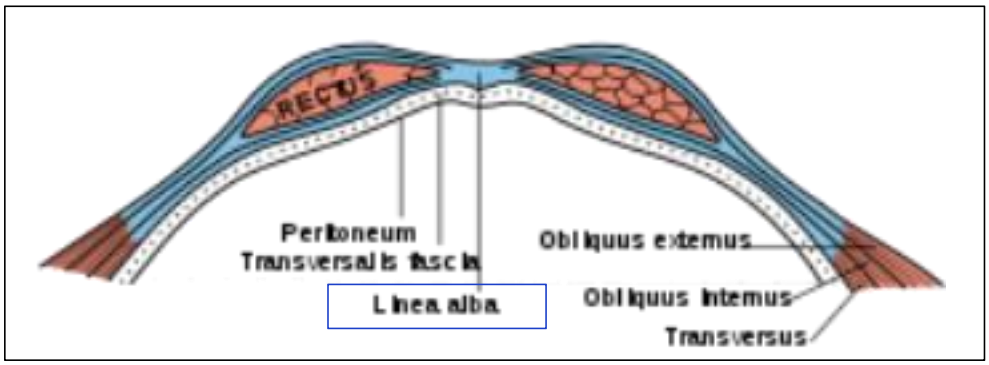

•During pregnancy , linea alba changes in color to appear brown , or blackish (this one of the signs / indicative of pregnancy along with darkening of areolas which are the areas around the nipples)

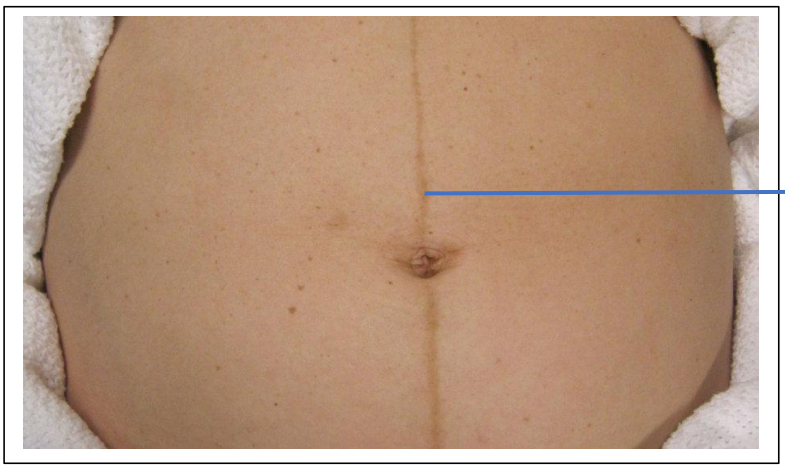

Black line , aka linea nigra . (During pregnancy)

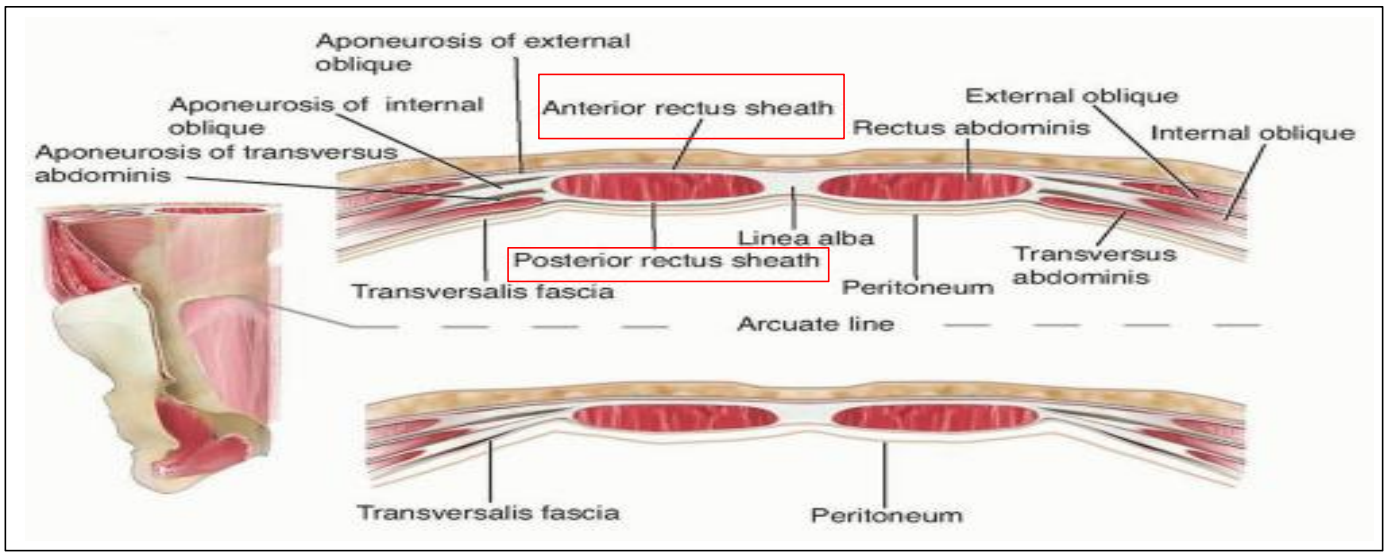

•Anterior rectus sheath extends from the xiphoid process(superiorly)all the way down to insert into pubic symphysis and body of the pubic ,so it's called to be continuous .

•Whereas , the posterior rectus sheath extends to a point midway b/w the umbilicus and the pubic symphysis , marked by the arcuate line .

•Arcuate line (aka Doulgas' line) ; abdominal horizontal line that demarcates the lower limit of the post rectus sheath .

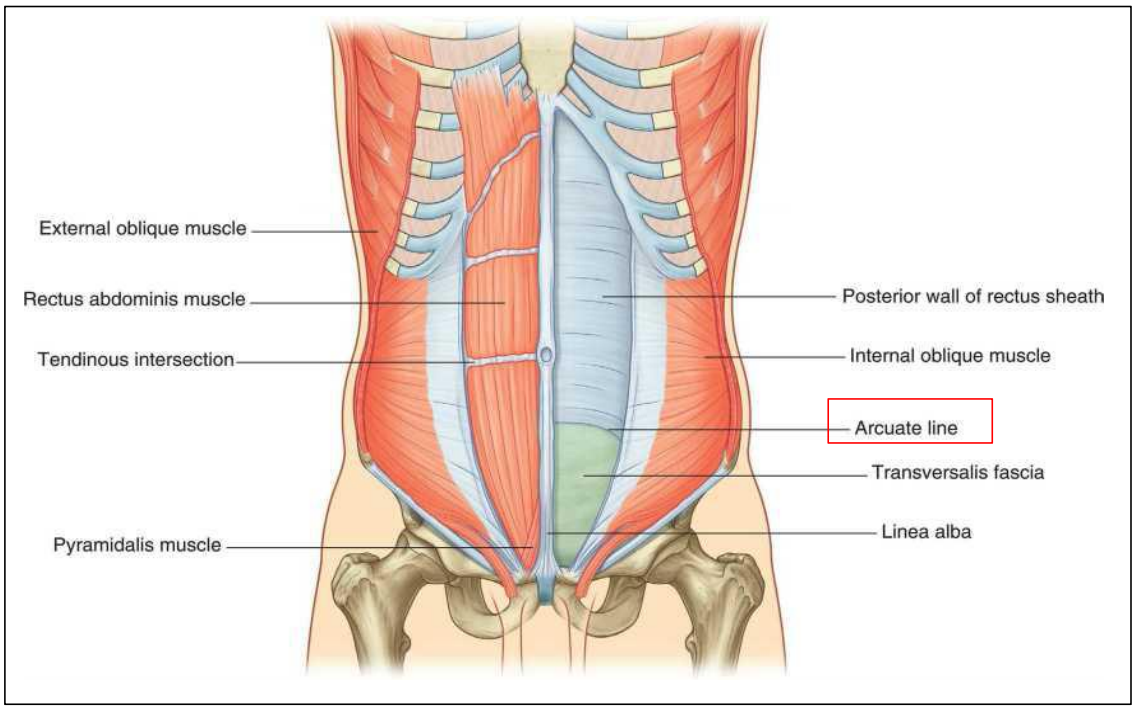

•Behind the post rectus sheath , Transversalis Fascia deep to it is the peritoneum .

Memorize the order :

Anterior Rectus Sheath >Rectus Abdominis Muscle >Posterior Rectus Sheath >Transversalis Fascia >Peritoneum >Greater sac of the abdomen

•Behind the Rectus Abdominis , just along the posterior rectus sheath , Inferior epigastric a. and Superior epigastric a. are found .

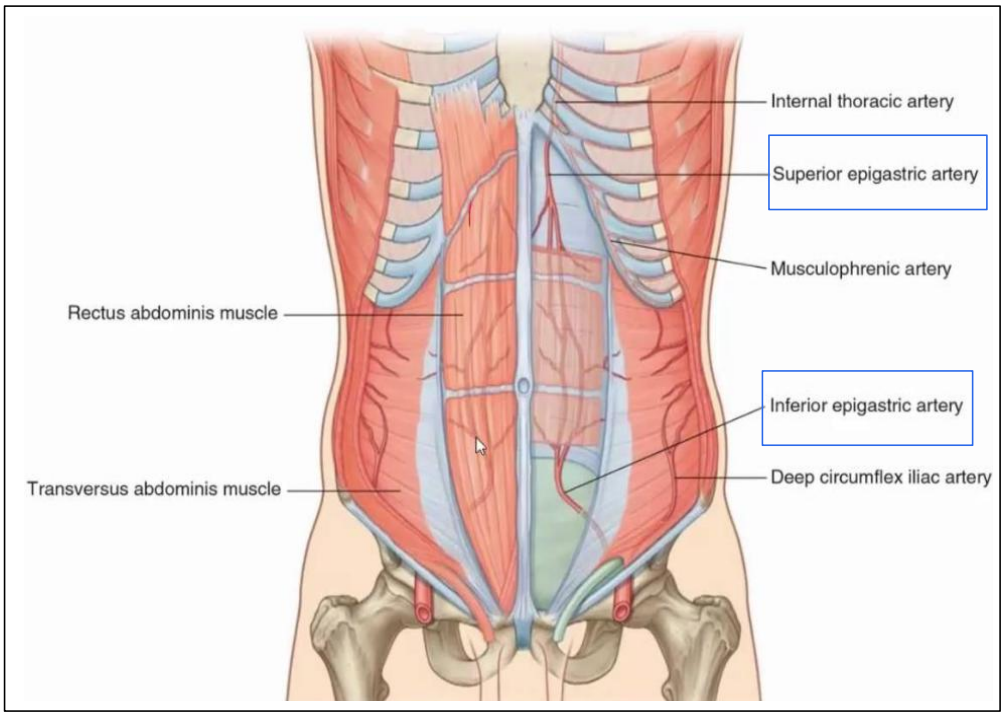

So,What is *found within the rectus sheath* ?

(1) Rectus Abdominis Muscle (b/w the two sheaths).

(2) Arteries (Sup epigastric a. and Inf epigastric a.) ;behind the muscle ,anterior to the post rectus sheath .

(3) Intercostal Nerves (T7-T11)and the subcostal nerve (T12) ;these are responsible for innervation of the muscle ,too.

(4) Lymphatic Vessels

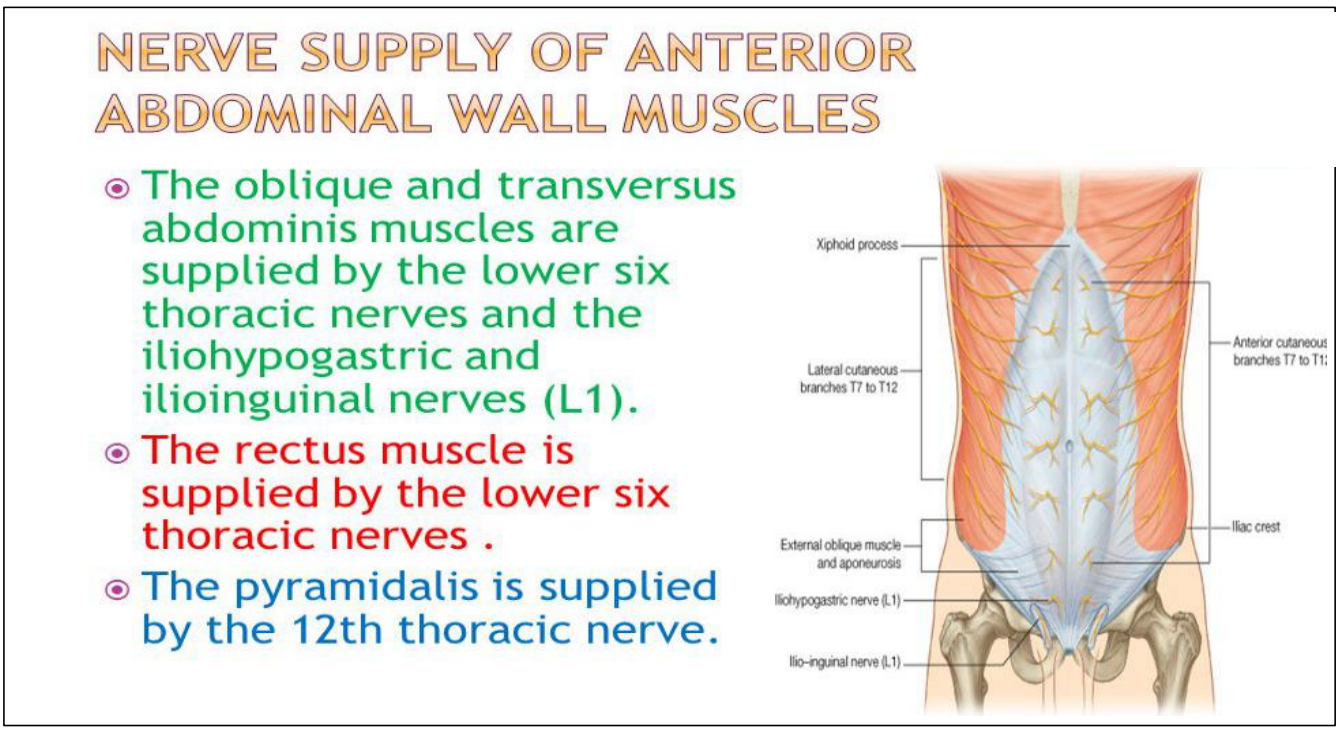

(2) External Oblique Muscle

•Origin :

Muscular slips from the outer surfaces of The lower 8 ribs(V –XII)

•Insertion :

Anterior half of the iliac crest

The three abdominal wall flat muscles :

(1) External Oblique .

(2) Internal Oblique .

(3) Transversus Abdominis .

•Posterior part of the muscle is free .

•External oblique muscle interdigitates with 2 muscles :

(1) Serratus Anterior Muscle .

(2) Latissimus Dorsi Muscle .

•Direction of muscle fibers : Medially , downward ,forward .

•Structurally , it is of 2 components ; fibrotic(Laterally placed muscle fibers) and large aponeurotic component(Medial part) which covers anterior part of the abdominal wall to the midline ,where the aponeuroses are enwined , forming the linea alba(Xiphoid process–sup– to pubic symphysis–inf–)

•Lower end of the membraneous part (apponeurotic part) ,folded backward ,upward ,where it is attached to(inserted at) the ASIS and Pubic tubercle (this lower end is called Inguinal lig)

•Remember ; inguinal lig extends from ASIS to Pubic tubercle , continues to the pubic crest reaching the symphysis pubis .

•Inguinal lig will form a point of origin of Internal oblique ;which originates from lateral 2/3 of the lig along with other sites ,and transversus abdominis ;which originates from lateral 1/3 of the lig along with other sites.

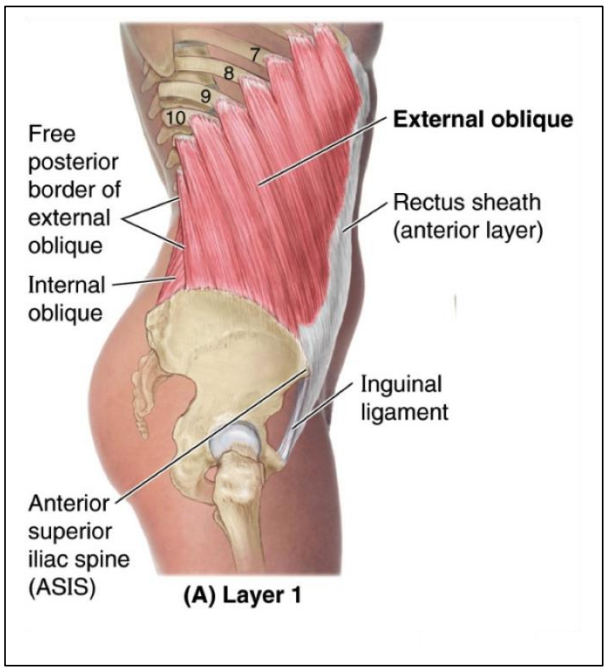

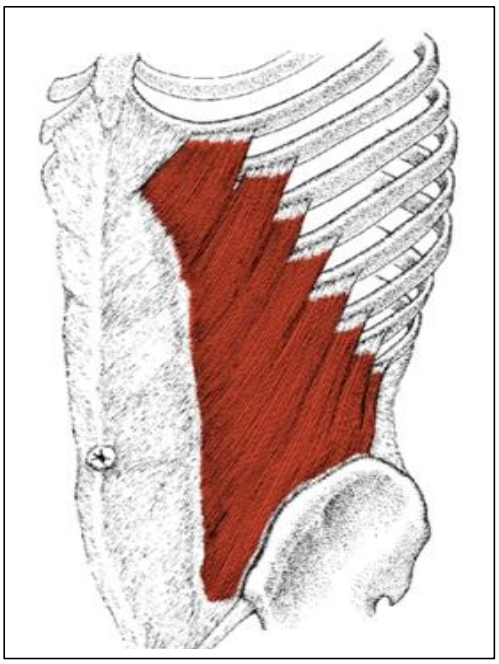

•Triangular shape defect , found within the E oblique muscle , just above the iliac crest is called Superficial Inguinal ring ,in females round lig passes through this ring , in males it is the spermatic cord which passes through the ring.

>The superficial ring forms the exit of inguinal canal , whereas the deep inguinal ring,which is on the other end of the canal, forms the enterance .

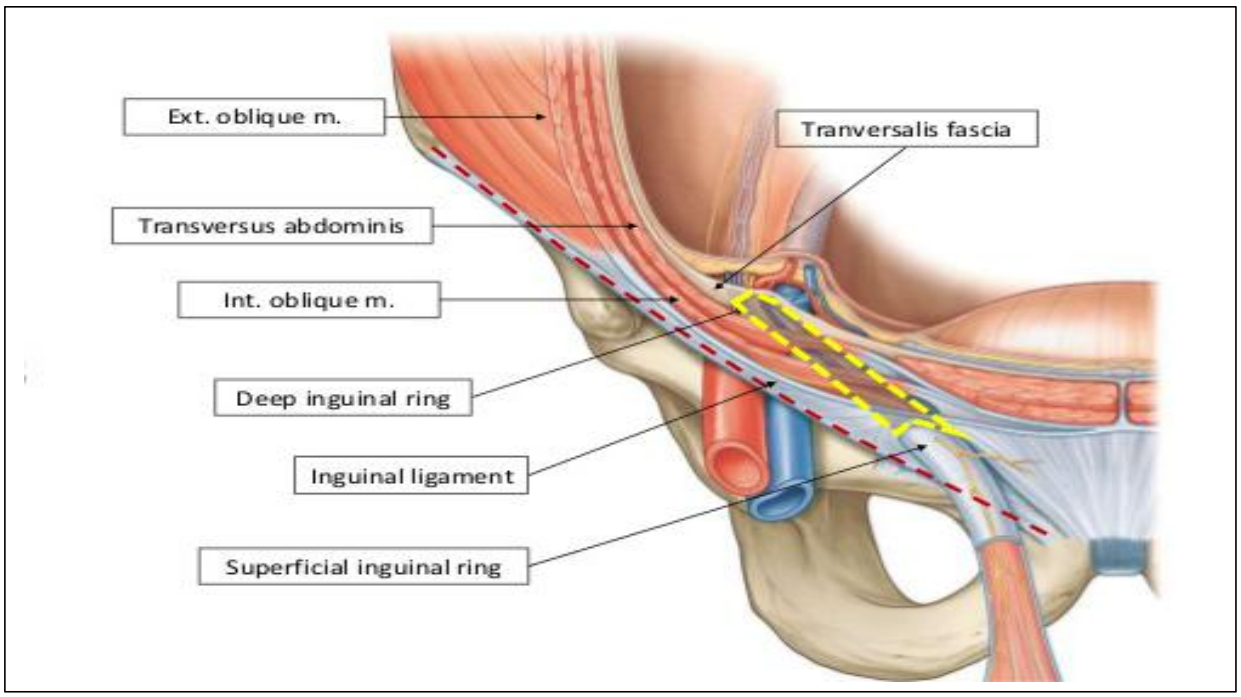

•Relations of inguinal ring (superficial inguinal ring) :

(1) Found within the aponeurosis of External oblique .

(2) Above the pubic crest .

(3) Superolateral to the pubic tubercle .

(4) Medial crura , by pubic crest.

(5) Lateral crura , by pubic tubercle .

(6) Inferiorly : Inguinal lig.

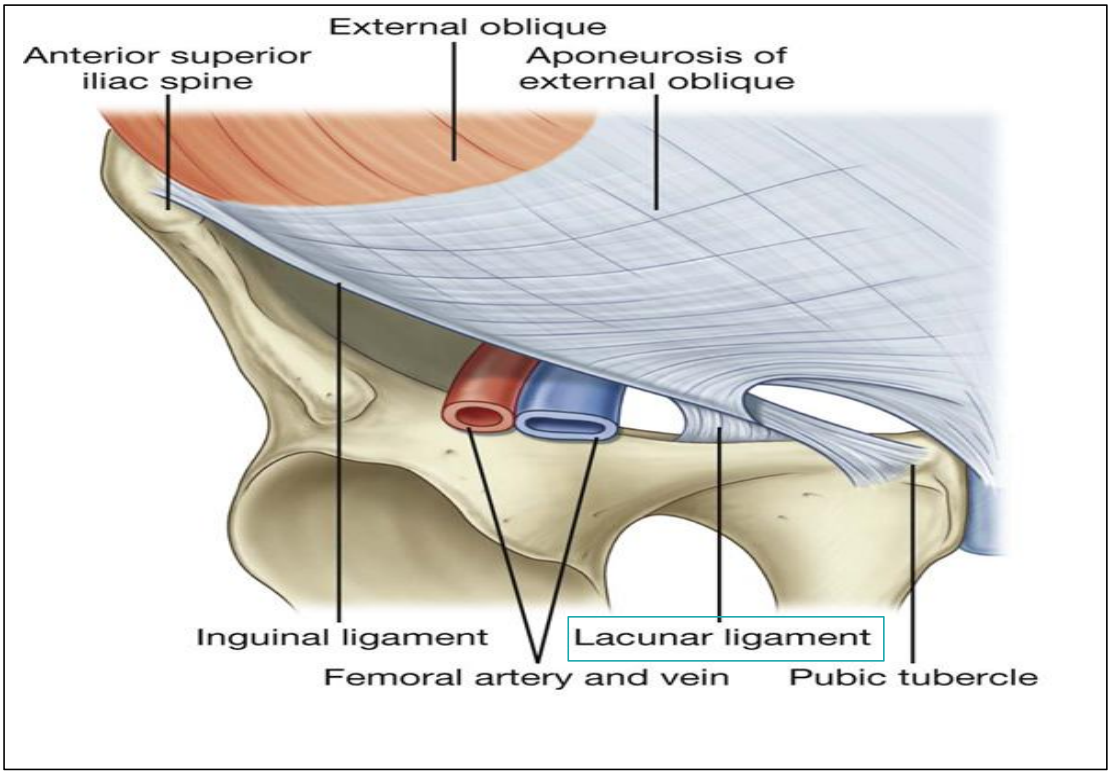

•Backward , lateral reflection of the aponeurosis of external oblique forms -->Lacunar lig , which is attached to the pectineal line of pubis.

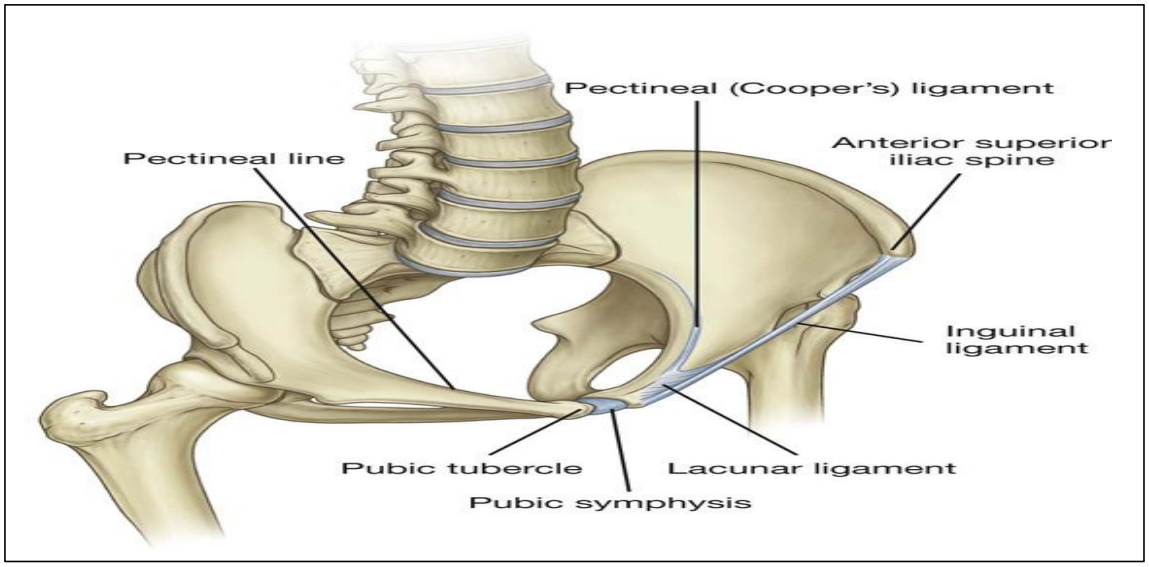

So, revise origin and insertion of EAO and its action :

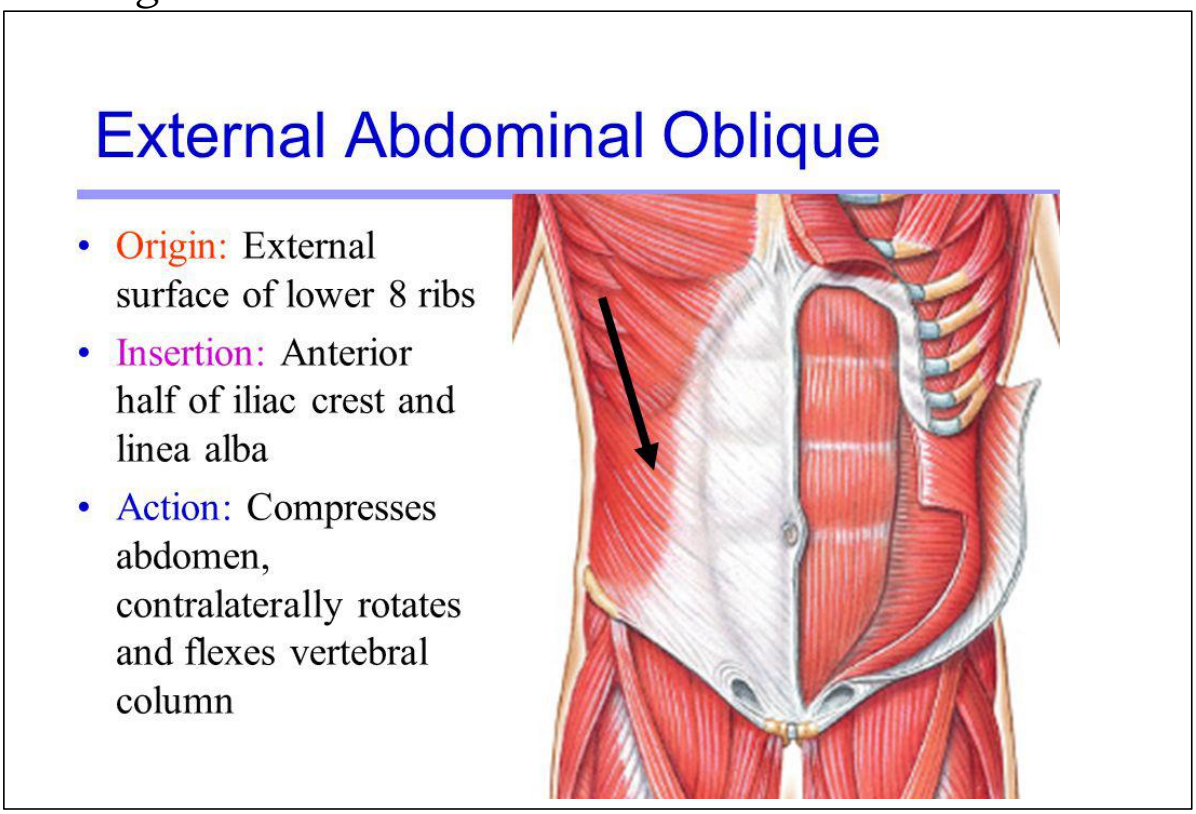

(3) Internal Oblique Muscle

•Origin :

Thoracolumbar fascia ,Lateral 2/3 of inguinal lig and ant 2/3 of iliac crest .

•Insertion :

Passes anteromedially , as aponeurosis which blends into the linea alba at the midline .

(1)Its lower(inferior) part continues down ,where it gets inserted into pubic crest .

•Conjoint tendon ; formed by union of lower part of apponeurosis of the internal oblique and the transversus abdominis as it inserts into the pubic crest.

(3) Its superior part , gets inserted into the costal cartilages of lower 4 ribs .

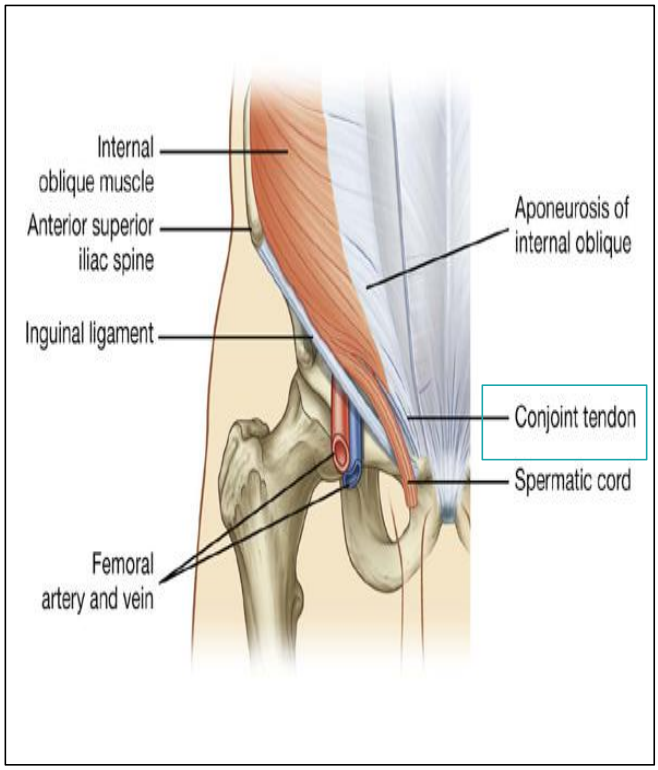

(4) Transversus Abdominis

•Origin :

Thoracolumbar region ,lateral 1/3 of inguinal lig , deep surface of costal cartilages (VII –XII) , anterior 2/3 of iliac crest .

•Insertion :

Medially , it becomes membraneous (Aponeurosis) which ends in linea alba , also the lower part gets inserted into the pubic crest , during which it forms the conjoint lig with the lower part of internnal oblique .

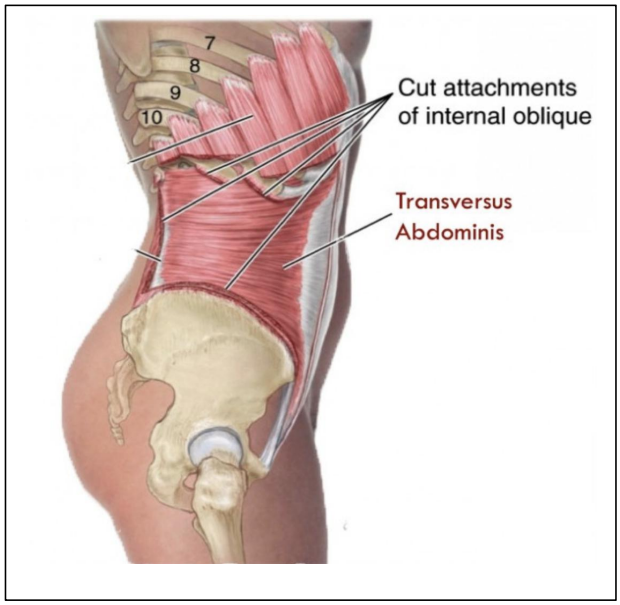

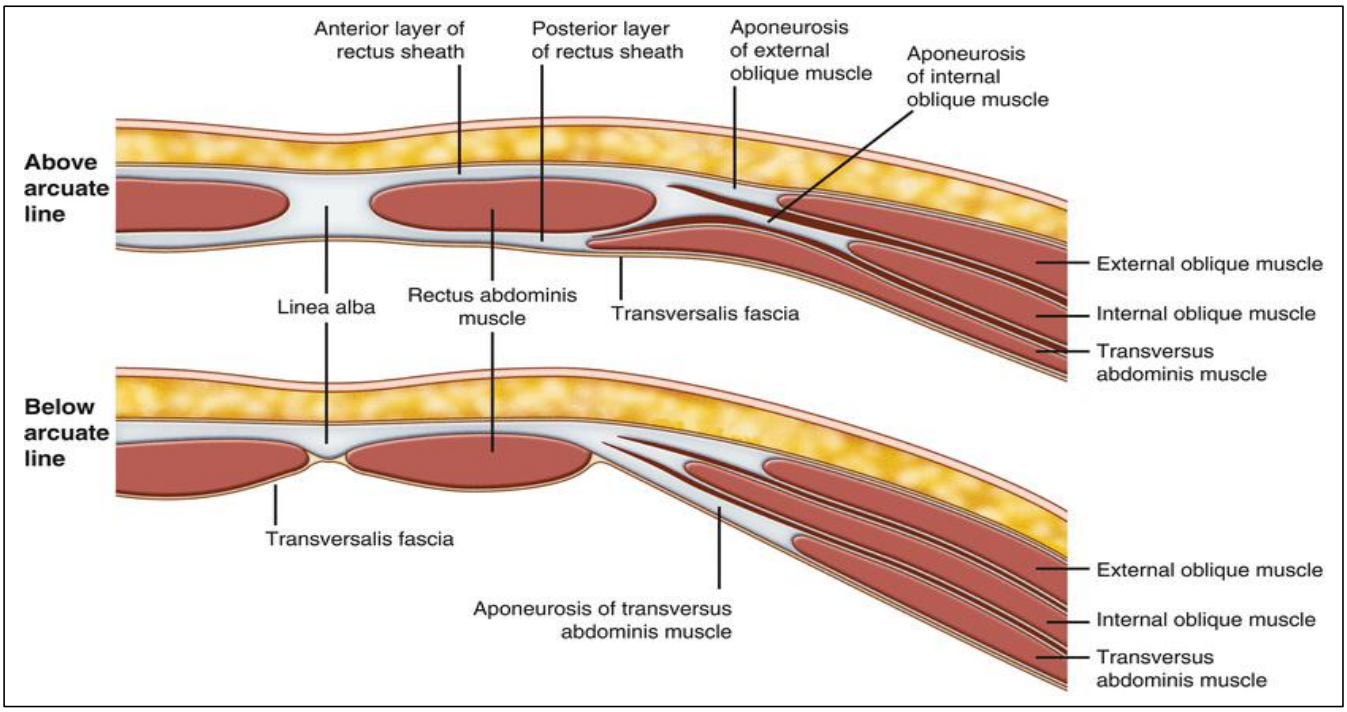

•Anterior the the xyphoid process , rectus abdominis sheath is only formed by the aponeurosis of external oblique muscle (anterior rectus sheath) , at this level no posterior rectus sheath found .

•Below the xiphoid process all the way to a point midway b/w the umbilicus and pubic symphysis :

<•>Anterior rectus sheath is made up by

(1) A poneurosis of external oblique .

(2) Anterior division of internal oblique aponeurosis .

<•>Posterior rectus sheath is made up by

(1) Posterior division of internal oblique aponeurosis .

(2) Aponeurosis of transversus abdominis .

•At the level of arcuate line , the posterior rectus sheath ends .

•Below the arcuate line , no posterior sheath found behind the rectus abdominis .

•Anterior rectus sheath , below the arcuate line is made up by aponeurosis of the following muscles :

(1) Internal Oblique. (2)Transversus Abdominis . (3)External Oblique .

Innervation of abdominal flat muscles :

(1) Innervated by T7-T11 and T12

(2) L1 -Doesn't innervate the rectus abdominis - .

Function(Action)of abdominal wall muscles :

(1)compress the abdomen

(2)Increase the pressure inside the abdomen , assisting in defecation , dilevary and urination .

(3)Flexion of the trunk , including lateral flexion

End of abdominal wall anatomy