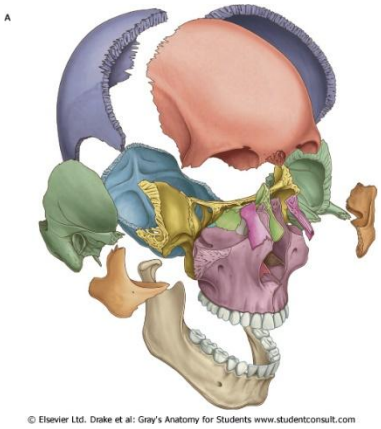

The Axial Skeleton I

The Skull

Midsagittal plane :divided the body into left and right side

Chest (ribs and sternum) are very attached to the axial region so they are considered apart if axial body)

Skull Bones

- **Serve as a muscular attachment (for any muscle the exist either in the face or in the back or in the neck)**

❖ **The skull is the body's most complex bony structure.**

❖ **The most superior part of the axial Skelton is the skull .**

❖ **Can be divided into two regions**:

1. **The cranium "Cranial bones"**
2. **Facial bones**

1) **The Cranium**

- protects the brain, organs (eye & nose) and serve as attachment sites of head and neck muscles

2) **Facial bones**

- Facial muscles usually have **no** attachment to bones except for few , they are called muscles of expression..
- Forms the framework of the face and the teeth
- Provide openings for the passage of air and food
- Anchor the facial muscles of expression

Developmental Aspects of the Skeleton:

Neonatal Skull (Skull of the new borne)

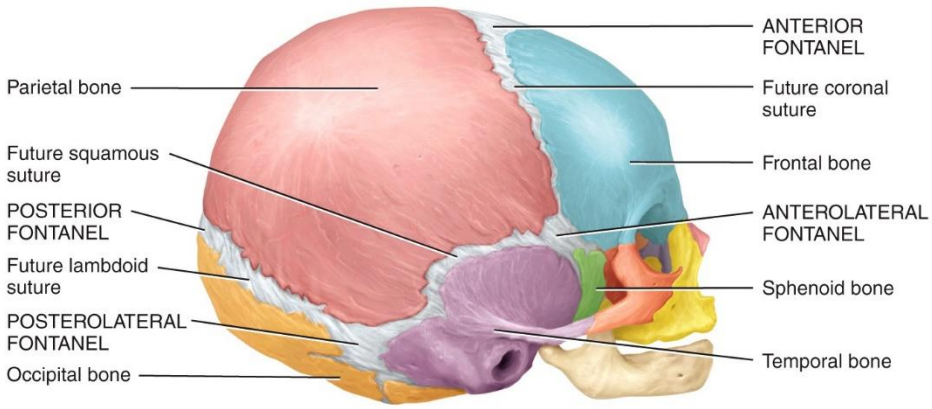

(a) Right lateral view

- Usually bones of the skull are fused together
- Baby have skull which is not completely fused together to make delivery (process of birth) easier and to prevent breaking of skull bones .
- The head will be smaller than unusual so the delivery will be easier
- In Head delivery because the bones are not completely fused the head become smaller by overlap
- Sutures are exciting between all the bones
- Fontanel is used to indicate what the states of baby is
- The sutures between bones in baby skull will fused and leave a real sutures because sutures in baby skull are unreal because are not fused and there is connective tissue membrane between the bones

(للتوضيح: الانسجة الضامة تكون بين اجزاء العظمة الواحدة ، يعني ان العظمة في جمجمة الرضيع تكون مقسمة الى اكثر من قسم ، مثال عليها ال occipital bone فهذه العظمة تكون مقسمة الى خمسة اجزاء في جمجمة الطفل ويفصل بينها النسيج الضام)

Developmental Aspects of the Skeleton: Growth Rates

- At birth, the cranium is huge relative to the face then the human grow and the size of cranium become less relative to the face .
- Mandible and maxilla are short but lengthen with age.
- The arms and legs grow at a faster rate than the head and trunk, leading to adult proportions (The head is less than body)

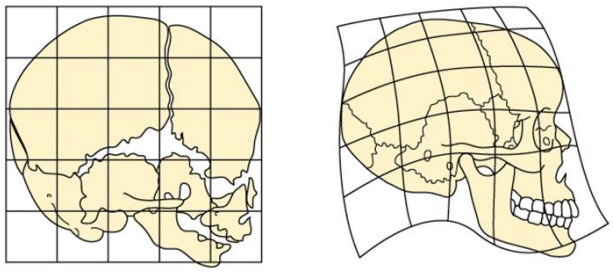

(a)

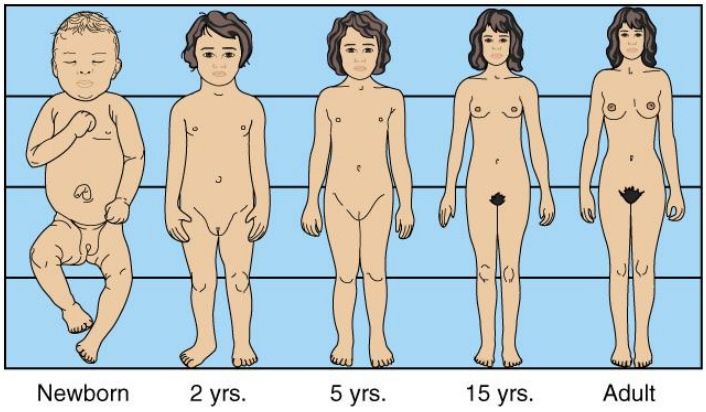

(b)

Surface markings

- Vertex is the most flat place in the posterior skull

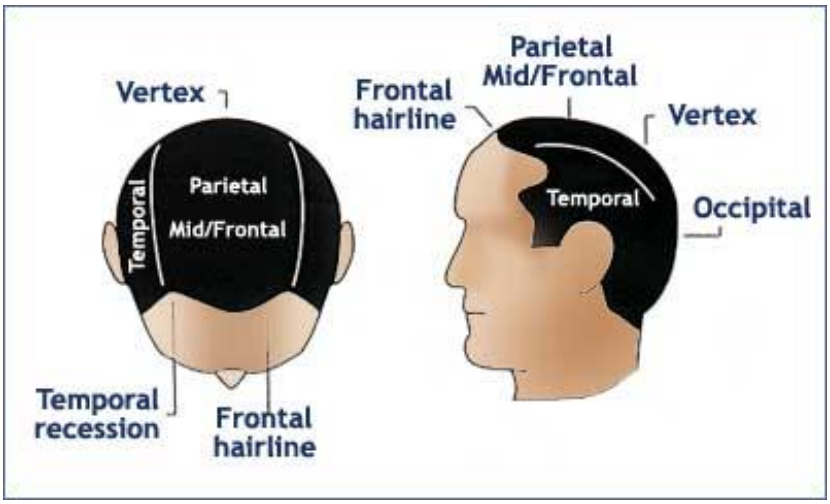

- Bregma – the point of intersection of the coronarian suture with the sagital one, and it corresponds to the vertex of the vault, or to the highest point of the skull(The bregma Is the most superior part of the skull .)
- Glabela – corresponds to the median area, which is situated between the superciliary arches
- Nasion – the point of intersection of the fronto-nasal suture with the median line

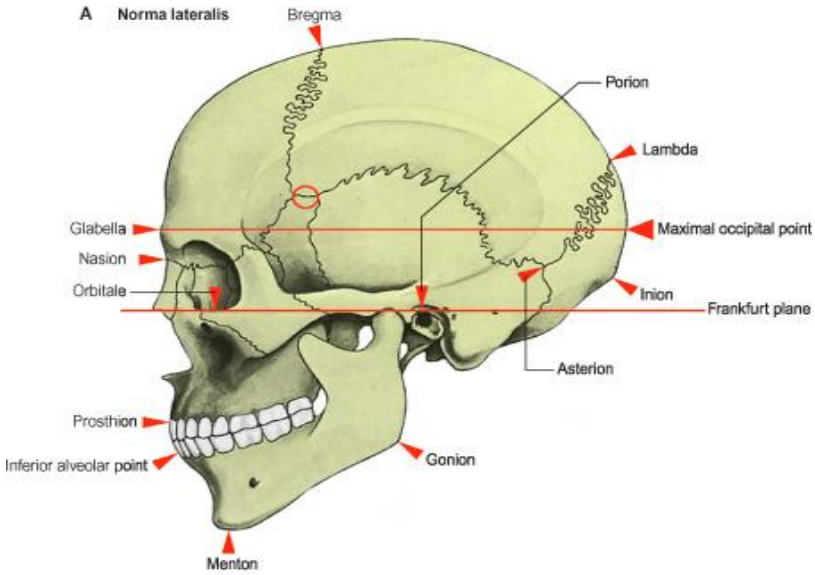

- **Gonion (is the angle of the mandible)**

Anatomy of the skull:

- Skull is divided into two regions:
  1) FACIAL BONES are Irregular bones (, sometimes are flat bones or part of these bones could be flat and the same bone has flat part and Irregular part) encircles and forms the orbital, the oral and nasal cavities:
     - Fourteen bones of which only the mandible and the vomer are unpaired.
     - The paired bones are the maxillae, zygomatics, nasals, lacrimals, palatines, and inferior conchae
  2) CRANIAL BONES are flat thin bones and remarkably strong for their weight.
     - Eight cranial bones – two parietal, two temporal, one each frontal, one occipital, one sphenoid, and an ethmoid bone.

FACIAL BONES The Frontal Bone:

- Forms the anterior portion of the cranium (The Forehead)
- Articulates (attached) posterior with two parietal bones through the Coronal suture
- Major markings are:
  - The supra-orbital margin (with a notch and a formain).
  - Glabella.
- Participate in forming the anterior cranial fosse.
- L shape
- The inferior border of the frontal bone make the superior margin of the orbital bone
- Contain to process : two zygomatic process and two maxillary process
- Contains the frontal sinuses
  - Two air filled cavities that are located within the bone “internal”

Anterior or frontal View “Frontal Bone”:

- Squama means flat
- Margines : حفة
- Process :is usually extension of the bone will meet another bone or to complete the structure ,it will take the bone name
- Fontanel : the area between the bones

Suture : the fusion between 2 bones

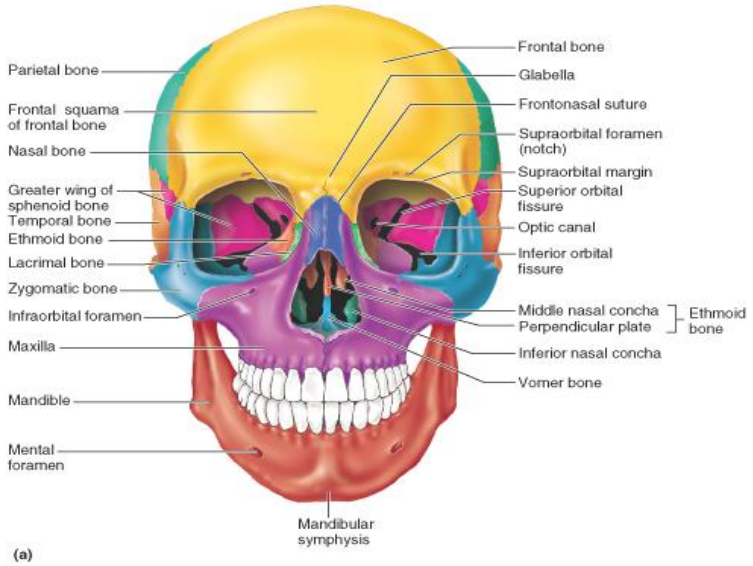

- Facial keystone bones that articulate with all other facial bones, except the mandible
- Medially fused bones that make up the upper jaw and the central portion of the facial skeleton
- Major markings include frontal and zygomatic processes, the alveolar margins, inferior orbital fissure, and the maxillary sinuses

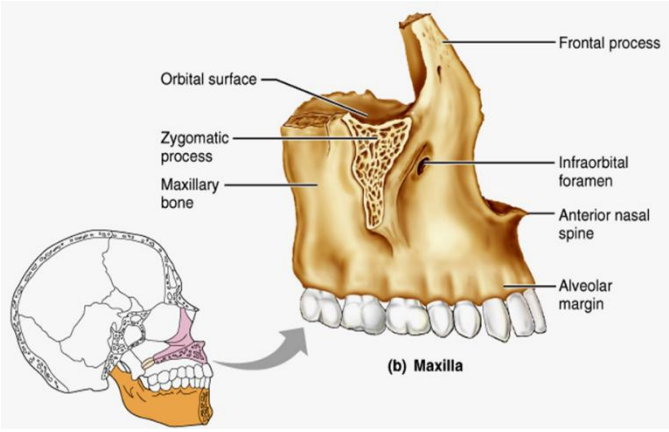

Maxilla and Zygomatic Bone

- The zygomatic bone has two process and one body ,
- The process of maxilla is very important because they are jointed with frontal bone and form apart of medial wall of orbit
- The one process of zygomatic bi=one which goes superior is called the frontal process of the zygomatic and the one which goes lateral is the temporal process of the zygomatic bone and it will need another process longer ,and this process called the zygomatic process of the temporal bone ,and together will form the arm of the face .

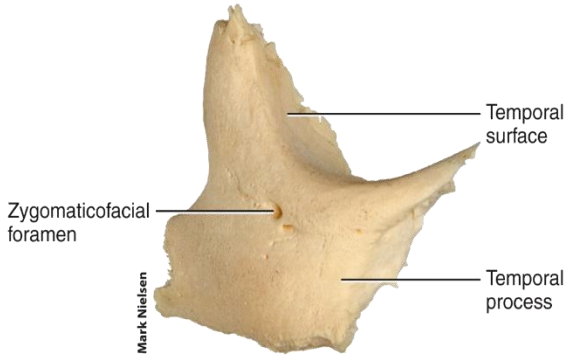

(b) Right zygomatic bone, lateral view

Anterior or frontal View "Zygomatic and Nasal bones":

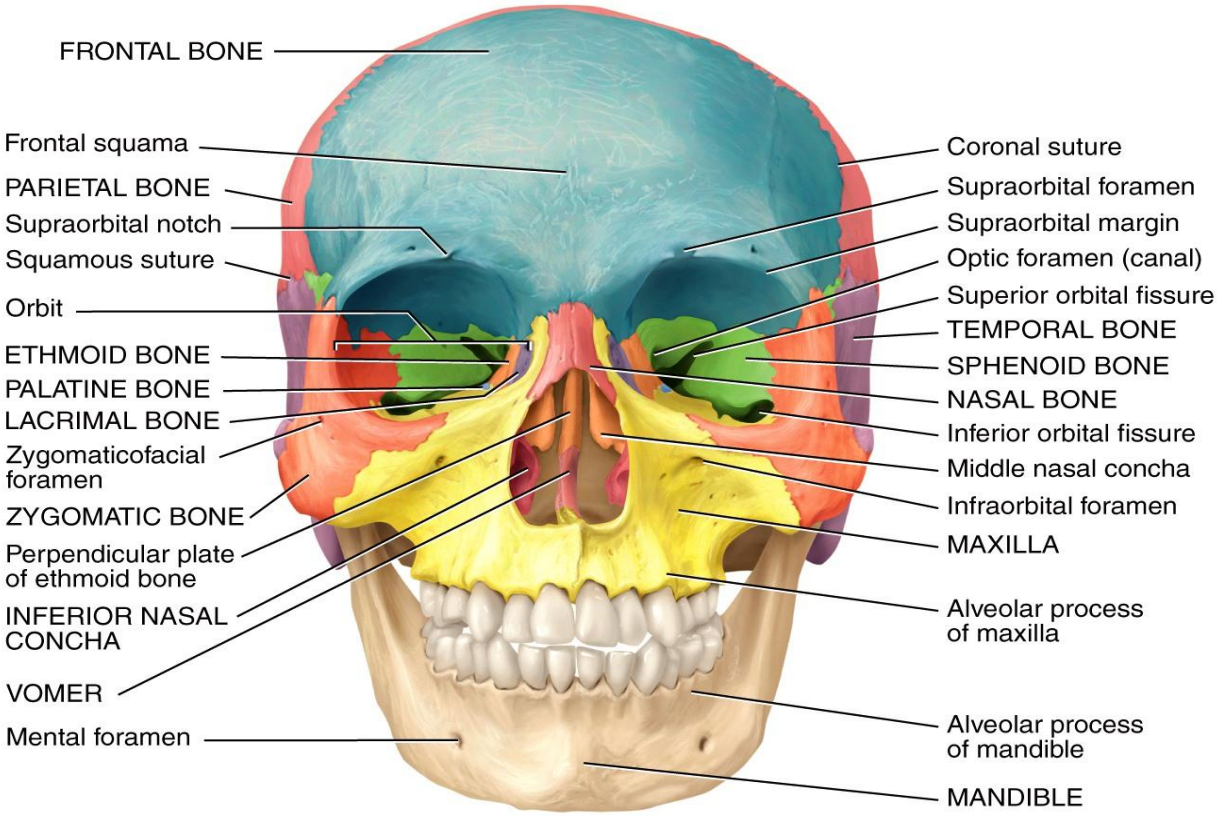

(a) Anterior view

The Orbit:

1) A bony cavities in which the eyes are hosted and cushioned by fatty tissue.

2) Formed by the participation of seven bones:
   a) Frontal.
   b) Sphenoid.
   c) Zygomatic.
   d) Maxilla.
   e) Palatine.
   f) Lacrimal.
   g) Ethmoid

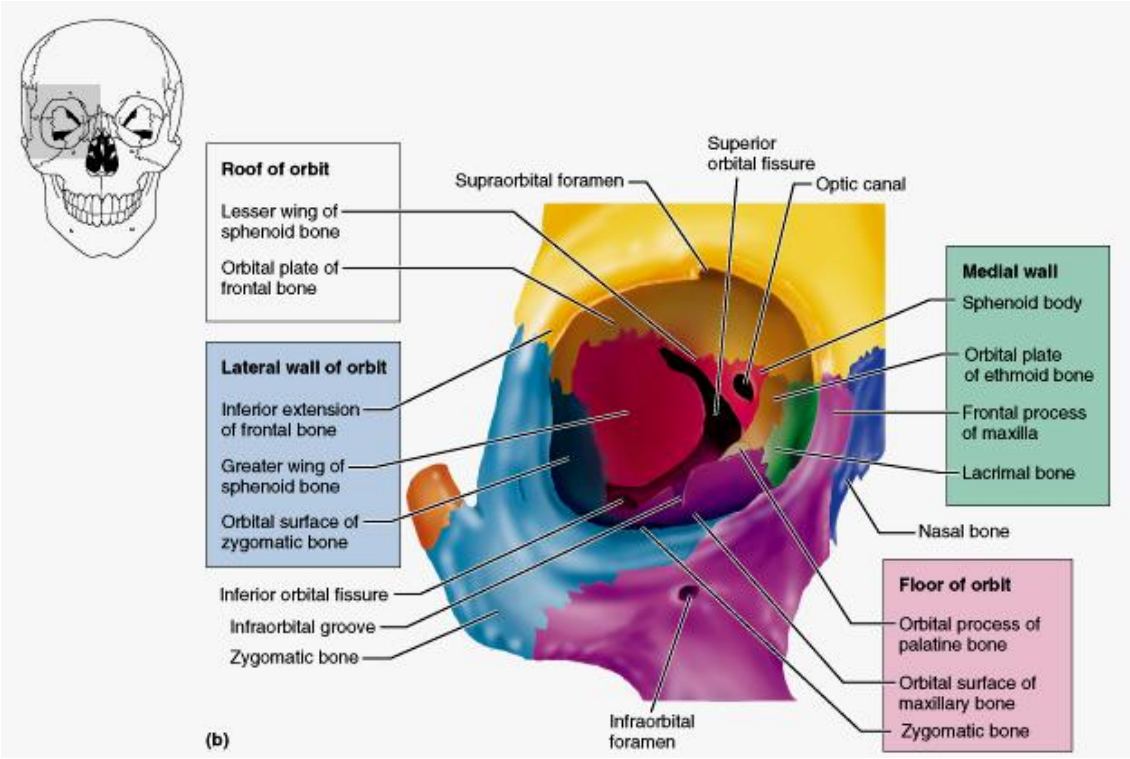

- The maxilla and zygomatic bone form the inferior border* of the orbit cavity .
- Superiorly the orbital cavity is formed from frontal the frontal body .
- The lateral part of the orbital cavity is formed from the zygomatic and the inferior part of the frontal bones

- Medially it is formed from the maxilla and frontal bones
- The process of the maxilla is very important because it will articulate with frontal bone and form part of the medial wall

Note : هناك بعض الحالات الناتجة من تجمع السوائل او نقصانها في الدماغ

1) Hydrocephalus : the anterior foramen bulge
2) Dehydration : lost of fluid in the body

So the foramen are used to indicate what states of the baby will be

Witten by : Hadeel Al_hawawsheh

Editing by : Lina Allan

Best wishes